



Clinical effects and treatment of envenoming by *Hoplocephalus* spp. snakes in Australia: Australian Snakebite Project (ASP-12)

G.K. Isbister^{a,b,*}, J. White^c, B.J. Currie^d, M.A. O'Leary^b, S.G.A. Brown^{e,f}, for the ASP Investigators

^a Discipline of Clinical Pharmacology, University of Newcastle, c/o Calvary Mater Newcastle, Edith St, Waratah NSW 2298, Australia

^b Department of Clinical Toxicology and Pharmacology, Calvary Mater Newcastle, NSW, Australia

^c Department of Toxinology, Women's and Children's Hospital, Adelaide, SA, Australia

^d Menzies School of Health Research and Northern Territory Clinical School, Darwin, Northern Territory, Australia

^e Centre for Clinical Research in Emergency Medicine, Western Australian Institute for Medical Research, Royal Perth Hospital, Australia

^f University of Western Australia, WA, Australia

ARTICLE INFO

Article history:

Received 20 June 2011

Received in revised form 15 September 2011

Accepted 22 September 2011

Available online 28 September 2011

Keywords:

Hoplocephalus

Snake venom

Antivenom

Envenoming

Stephens banded snake

ABSTRACT

There is limited information on envenoming by snakes of the genus *Hoplocephalus* from Eastern Australia. We investigated the clinical and laboratory features of patients with definite *Hoplocephalus* spp. bites including antivenom treatment, recruited to the Australian Snakebite Project. There were 15 definite *Hoplocephalus* spp. bites based on expert identification including eight by *Hoplocephalus stephensi* (Stephen's banded snakes), four by *Hoplocephalus bungaroides* (broad-headed snake) and three by *H. bitorquatus* (pale-headed snake). Envenoming occurred in 13 patients and was similar for the three species with venom induced consumption coagulopathy (VICC) in all envenomings. Seven patients had an INR >12 and partial VICC, with only incomplete fibrinogen consumption, occurred in three patients. Systemic symptoms occurred in eight patients. Myotoxicity and neurotoxicity did not occur. *H. stephensi* venom was detected in all three *H. stephensi* envenomings (1.1, 44 and 81 ng/mL) for whom pre-antivenom blood samples were available, and not detected in one without envenoming. In two cases with post-antivenom blood samples, venom was not detected after tiger snake antivenom (TSAV) was given. *In vitro* binding studies demonstrated that TSAV concentrations of 50mU/mL are sufficient to bind the majority of free *H. stephensi* venom components at concentrations above those detected in envenomed patients (100 ng/mL). Eleven patients received antivenom, median dose 2 vials (Range: 1 to 5 vials), which was TSAV in all but one case, where polyvalent antivenom was used. Immediate hypersensitivity reactions occurred in six cases including one case of anaphylaxis. Envenoming by *Hoplocephalus* spp. causes VICC and systemic symptoms, making it clinically similar to brown snake (*Pseudonaja* spp.) envenoming. Based on *in vitro* studies reported here, patients may be treated with one vial of TSAV, although one vial of brown snake antivenom may also be sufficient.

© 2011 Elsevier Ltd. All rights reserved.

1. Introduction

The genus *Hoplocephalus* includes three different species of snakes that are relatively rare and confined to

small geographical regions in Eastern Australia. Stephen's banded snake (*Hoplocephalus stephensi*) is the most common and distributed throughout northern coastal New South Wales (NSW) (Figs. 1 and 2). The broad headed snake (*Hoplocephalus bungaroides*) is confined to a smaller region in central coastal NSW and the pale headed snake (*H. bitorquatus*) to a larger but relatively unpopulated region of south western Queensland (Figs. 1 and 2). All species are relatively commonly kept by herpetologists and private

* Corresponding author. Discipline of Clinical Pharmacology, University of Newcastle, c/o Calvary Mater Newcastle, Edith St, Waratah NSW 2298, Australia. Tel.: +61 2 4921 1211; fax: +61 2 4921 1870.

E-mail address: geoff.isbister@gmail.com (G.K. Isbister).

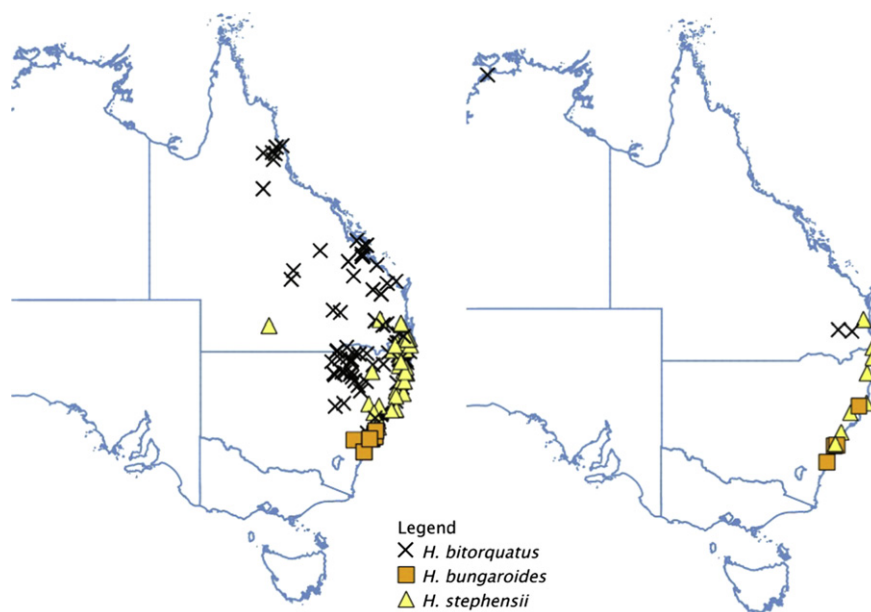


Fig. 1. Distribution maps of specimens of *H. stephensi* (▲), *H. bungaroides* (■) and *H. bitorquatus* (×) from museum data (left panel) compared to locations of bites by the three species (right panel).

collectors and most previously reported bites by *Hoplocephalus* snakes have been in these people (Flecker, 1952; Comadira and Green, 1995; Fry et al., 2000; Sutherland and Tibballs, 2001; Chew et al., 2003; Hession, 2007).

Hoplocephalus species are currently included as part of the tiger snake group with the tiger snakes (*Notechis* spp.) and the rough-scale snake (*Tropidechis carinatus*) (White, 2001; Gan et al., 2009). This inclusion is based on clinical experience and a small number of reported cases (Flecker, 1952; Comadira and Green, 1995; Fry et al., 2000; Sutherland and Tibballs, 2001; Chew et al., 2003; Hession, 2007), and because bites by *Hoplocephalus* spp. are often detected in the tiger snake well on the snake venom detection kit (sVDK). On this basis tiger snake antivenom (TSAV) is recommended for the treatment of *Hoplocephalus* bites (White, 2001), but this has not been confirmed by *in vitro* studies of the venoms.

The aim of this investigation was to report a series of cases of clinical envenoming by all three species of *Hoplocephalus* snakes. In addition, we aimed to determine the efficacy and dose of antivenom for *Hoplocephalus* envenoming by investigating the binding of TSAV to *H. stephensi* venom and measuring the concentrations of *H. stephensi* venom in patients' blood before and after antivenom.

2. Materials and methods

The study was a prospective cohort study of *Hoplocephalus* envenoming cases from the Australian Snakebite Project (ASP) and an *in vitro* examination of TSAV binding to *H. stephensi* venom.

2.1. Materials

H. stephensi (Stephen's banded snake), *N. scutatus* (Common tiger snake) and *T. carinatus* (Rough scale snake)

venoms were purchased from Venom Supplies, South Australia. Each venom is pooled from multiple milkings of snakes. TSAV (Batch # 10702) was purchased from CSL Ltd. Polyclonal monovalent rabbit IgG to *H. stephensi* venom was prepared as previously described and used in carbonate buffer (50 mM, pH 9.6) (Isbister et al., 2010a, b). Bovine serum albumin (BSA) and tetramethylbenzidine (TMB) were purchased from Sigma. PBS is phosphate-buffered saline. Rabbit IgG antibodies were biotinylated using EZ-Link Sulfo-NHS-LC-Biotin (Pierce # 21335) and streptavidin-conjugated horseradish peroxidase was purchased from Millipore.

2.2. Patients and patient samples

All cases of *Hoplocephalus* envenoming were recruited as part of ASP. ASP is a multicentre prospective study of definite or suspected snake bites from over 120 Australian hospitals. The study design has been previously described (Isbister et al., 2008; Gan et al., 2009; Churchman et al., 2010) and approval has been obtained from all Human Research and Ethics Committees covering institutions involved.

Clinical information, laboratory testing and any treatment is recorded on datasheets for all patients recruited to ASP. This information is entered into a purpose-designed relational database (Microsoft Access™). Based on the clinical and laboratory features the clinical envenoming syndrome(s) were defined in each patient based on a previously used classification (Table 1) (Ireland et al., 2010). Clinical features of any hypersensitivity reactions were recorded and graded according to Brown (2004) and a diagnosis of anaphylaxis made if a reaction met international consensus criteria (Sampson et al., 2006). Multiple serum (or plasma) samples are collected from each patient

recruited to ASP for venom detection and quantification. Samples are spun, aliquoted, frozen and then stored at –80 °C until assayed.

We searched the ASP database of 1017 cases of suspected or definite snakebite for the period January 2002 to March 2011 for cases of snake bite where the snake was expertly identified as a *Hoplocephalus* species or the snake was suspected to be a *Hoplocephalus* species based on geography, sVDK positive for tiger snake and patient description of the snake. In these latter cases enzyme immunoassay (EIA) was used to confirm if *Hoplocephalus* venom was detectable in serum samples from the patient. The snake venom detection kit (sVDK) is a commercially available qualitative enzyme immunoassay kit that can detect venom at the bite site or in urine. It gives a positive or negative to each of the venoms of the five major




Fig. 2. Images of specimens of *H. stephensi* (A), *H. bungaroides* (B) and *H. bitorquatus* (C). Photographs taken by J. White.

Table 1
Classification of envenoming syndromes in snake bite cases based on clinical effects and laboratory investigations based on Ireland et al. (2010).

Envenoming syndrome	Definition
Venom-induced consumption coagulopathy (VICC) (Isbister et al., 2010a, b)	
Complete	Consumption coagulopathy with undetectable fibrinogen and/or a raised D-Dimer (at least 10 times the assay cut-off or >2.5 mg/L) and an international normalised ratio (INR) > 3.0
Partial	Incomplete consumption coagulopathy with low but detectable fibrinogen, elevated D-Dimer and a maximum INR <3.0
Neurotoxicity	
Severe	Descending flaccid paralysis with either: two nerve groups involved [e.g. bulbar and ocular], respiratory muscle paralysis; or requirement for intubation or mechanical ventilation.
Mild	Paralysis of only one nerve group not meeting the criteria for severe neurotoxicity e.g. isolated ptosis
Myotoxicity	
Severe	Elevated creatine kinase(CK) >1000U/L associated with myalgia and/or muscle tenderness; local or generalised.
Mild	Elevated CK >1000U/L without associated clinical features.
Anticoagulant coagulopathy	Raised activated partial thromboplastin time (aPTT) with or without a mild elevation in the INR and a normal D-Dimer (<1 mg/L).
Thrombotic microangiopathy (TMA)	The presence of intravascular haemolysis on blood film, thrombocytopenia and an abnormal creatinine with or without acute renal failure.(Isbister, 2010)
Systemic symptoms	A minimum of three of nausea, vomiting, abdominal pain, diarrhoea, diaphoresis and headache

Australian snake groups: *N. scutatus* (Tiger snake), *Pseudonaja* spp. (Brown snakes), *Pseudechis* spp. (Black snakes), *Acanthophis* spp. (Death adder) or *Oxyuranus* spp. (Taipan).

The following data was extracted from the ASP database for the purpose of this study: demographic information (sex, age, geographical location, circumstances of the bite), information on the snake identification (expert identification, patient description), bite site, clinical effects (including envenoming syndromes), laboratory investigations and treatment (antivenom dose and timing).

2.3. Enzyme immunoassay (EIA)

Enzyme immunoassays were done as previously described (O’Leary et al., 2006; Kulawickrama et al., 2010). In brief, plates were coated with rabbit anti-*H. stephensi* IgG (2 µg/mL) at room temperature, and after an hour kept overnight at 4 °C. Plates were washed and blocked with 300 µL of 0.5% BSA in PBS. All washes were done with PBS

containing 0.02% TWEEN 20. After 1 h the plates were washed again and 100 μ L of human serum or plasma applied as dilutions of 0.1%–10% in blocking solution. After another hour the plates were washed three times and biotinylated rabbit anti-*H. stephensi* IgG (100 μ L, 0.5 μ g/mL in blocking solution) added. An hour later the plates were washed and streptavidin (100 μ L, 1 μ g/mL in blocking solution) added for 1 h. Plates were washed four times, TMB (100 μ L) added and colour allowed to develop for 4–10 min until the reaction was stopped with H_2SO_4 (50 μ L; 1 M). Serum samples were all measured in triplicate and average absorbance converted to a concentration from a standard curve. The limit of detection of the *H. stephensi* venom assay was 0.2 ng/mL.

2.4. In vitro antivenom binding assay

EIA was used to measure the amount of CSL TSAV required to bind increasing concentrations of free *Hoplocephalus* venom *in vitro*, as previously described (Isbister et al., 2007). The venoms of *H. stephensi* (100 ng/mL), *N. scutatus* (100 ng/mL) and *T. carinatus* (100 ng/mL) in blocking solution, were mixed with increasing concentrations of TSAV (0–100 mU/mL). The venom concentrations chosen were consistent with the highest concentrations found in envenomed patients for each of the snakes (Gan et al., 2009). The venom-antivenom mixtures were pre-incubated for 1 h at room temperature before being applied to a plated coated with antibody corresponding to the venom (i.e. rabbit anti-*H. stephensi* IgG for *H. stephensi* venom). Free venom concentration was then plotted against TSAV concentration to determine when free venom was no longer detectable.

2.5. Data analysis

For descriptive statistics median and interquartile ranges (IQR) were used unless the data was normally distributed. Standard curves were fitted by linear and non-linear regression. All graphs and analyses were done in GraphPad Prism version 5.03 for Windows, GraphPad Software, San Diego California USA, www.graphpad.com.

3. Results

3.1. Patient cases and venom concentrations

There were 15 definite *Hoplocephalus* spp. bites including eight by Stephen's banded snakes, four by broad-headed snakes and three by pale-headed snakes. Envenoming occurred in 13 patients. The two non-envenomed patients were bitten by identified *Hoplocephalus* snakes. The patient was a snake handler in eight cases and the snake was in captivity in another one. The remaining six cases - four by *H. stephensi* and one by *H. bitorquatus* and one by *H. bungaroides* - occurred from non-captive snakes. The majority of cases occurred within their natural distribution despite most being kept in captivity (see Fig. 1). All of the patients were male with a median age of 33 years (IQR: 23 to 50; Range: 9–55 years). The bite was on the upper limb in 14 cases (hand [3], finger [8] and thumb [3]) and on the foot in one case.

Envenoming was similar for the three species and venom induced consumption coagulopathy (VICC) occurred in all 13 cases. An INR >12 occurred in seven patients. Partial VICC with only incomplete fibrinogen consumption occurred in three patients, one *H. stephensi* and two *H. bitorquatus*. The median time until the INR recovered to less than 2 was 11.5 h (Fig. 3). Systemic symptoms occurred in eight patients. Myotoxicity, neurotoxicity, thrombotic microangiopathy and acute renal failure did not occur. There were no cases of major haemorrhage or deaths. Local effects were minimal with local pain and bruising (Fig. 4). A comparison of the clinical features for the three species is provided in Table 2 which suggest that bites by *H. bitorquatus* are less severe with a smaller proportion with complete VICC and systemic symptoms.

Bite site sVDK was done in nine patients and was positive for tiger snake venom in eight and black snake in one (*H. bitorquatus*). Urine sVDK was done in one other patient and was positive for tiger snake venom. Blood was available in four of the eight *H. stephensi* bites. Venom was detected in three envenomings (1.1, 44 and 81 ng/mL) and not detected in one *H. stephensi* bite without envenoming. In one of the three envenomings not treated with antivenom, venom was still detectable 17 h post-bite (0.7 ng/mL). Three *H. bungaroides* envenoming cases were tested - no venom was detected in two cases despite VICC, and 3.4 ng/mL in one with complete VICC and systemic symptoms. One *H. bitorquatus* envenoming case was tested and no venom was detected, despite the presence of VICC.

Eleven patients received antivenom, median dose 2 vials (Range: 1 to 5 vials), which was TSAV in ten cases and polyvalent antivenom in one case. No venom was detected after two vials of TSAV in the two envenomed *H. stephensi* cases treated with antivenom and no venom was detected after two vials of TSAV in the one *H. bungaroides* case where venom was detected pre-antivenom. Immediate hypersensitivity reactions occurred in six cases including one case of anaphylaxis with hypotension.

3.2. In vitro studies

Increasing concentrations of TSAV reduced the free venom concentration of *H. stephensi*, but not to the same

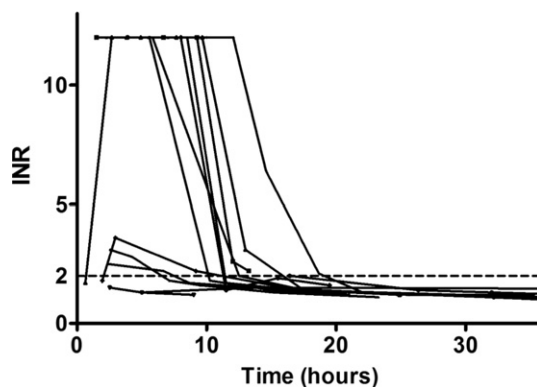


Fig. 3. Plots of the recovery of the coagulopathy comparing INR versus time for individual *Hoplocephalus* envenoming cases (black). Black dashed line is INR = 2.

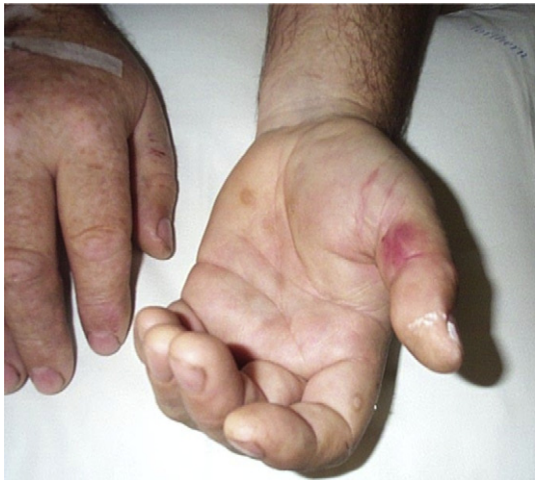

Fig. 4. Local bruising from a bite to the thumb.

degree as *N. scutatus* and *T. carinatus* venoms (Fig. 5). TSAV concentrations greater than 50mU/mL reduced free *H. stephensi* venom concentrations to less than 1 ng/mL (1%) (Fig. 5).

4. Discussion

In this study envenoming by all three *Hoplocephalus* spp. caused partial or complete VICC with no evidence of myotoxicity or neurotoxicity. Resolution of the coagulopathy was consistent with other Australasian elapids that cause VICC as shown in Fig. 3 (Isbister et al., 2009). Systemic symptoms occurred in just over half of the cases. These features of isolated VICC with only half of cases causing systemic symptoms make *Hoplocephalus* envenoming clinically closer to that of envenoming by *Pseudonaja* species (Brown snakes). However, most cases tested positive to tiger snake on the sVDK, despite a previous study indicating *Hoplocephalus* would not be reliably detected by sVDK (Clancy et al., 1997). Of the 13 envenomed cases, 11 were treated with TSAV based on current treatment recommendations (White, 2001) and this appeared to be effective based on post-antivenom venom concentrations in a limited number of patients

Table 2
Clinical features of envenoming for each of the three species of *Hoplocephalus*.

Clinical syndrome	<i>H. stephensi</i> N = 7	<i>H. bungaroides</i> N = 3	<i>H. bitorquatus</i> N = 3
VICC	7	3	3
Complete	6	3	1
Partial	1	0	2
Systemic symptoms	5	2	1
Nausea	5	2	1
Vomiting	5	1	0
Headache	2	2	2
Abdominal Pain	2	1	0
Diaphoresis	1	0	1
Diarrhoea	2	0	0

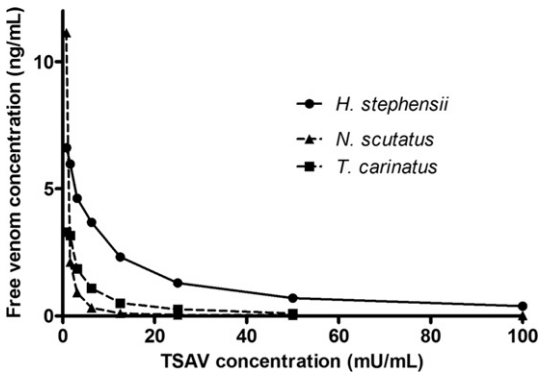


Fig. 5. The effect of increasing concentrations of TSAV on the amount of free venom detected by EIA for clinically relevant concentrations of *H. stephensi* venom (filled circle; 100 ng/mL) compared to *N. scutatus* venom (filled square; 100 ng/mL) and *T. carinatus* venom (filled triangle; 100 ng/mL). Data are plotted as free venom concentration measured versus TSAV concentration.

and *in vitro* binding studies. EIA using *H. stephensi* venom did not appear to be reliable in detecting venom from the other two species.

The clinical features we describe here are similar to previous cases where VICC was reported as the predominant feature (Flecker, 1952; Comadira and Green, 1995; Fry et al., 2000; Sutherland and Tibballs, 2001; Chew et al., 2003; Hession, 2007). Flecker reported a case of envenoming by *H. bungaroides* but no laboratory studies are provided (Flecker, 1952). The patient had significant local effects but the bitten finger was cut and a ligature applied for first aid. A more recent case of *H. bungaroides* envenoming was reported in Scandinavia from a captive snake (Chew et al., 2003). This patient had complete VICC that resolved over 24 h, minor electrocardiogram abnormalities that resolved over 8 h and a modest elevation in creatine kinase without clinical features of myotoxicity. They were given antivenom 11 h after the bite. The only other report of bites by *H. bungaroides* is in abstract form (Fry et al., 2000). Two cases were reported where VICC occurred with systemic symptoms and early collapse in one case (Personal communication, J White, 2006).

There are three previous reports of bites by *H. stephensi* (Comadira and Green, 1995; Fry et al., 2000; Hession, 2007). VICC was reported in all of these cases and the presence of systemic symptoms was consistent with our cases (Table 2). Early collapse was reported by Fry et al. (2000). There is only one previous report of envenoming by *H. bitorquatus*. (Sutherland and Tibballs, 2001) In our study envenoming by this snake appeared to be less severe, although this is based on only a small number of cases.

We have previously shown that there is little cross-reactivity between *H. stephensi* venom and both *N. scutatus* and *T. carinatus* using EIA in patients with suspected *T. carinatus* envenoming (Gan et al., 2009). This was in contrast to considerable cross-reactivity between *N. scutatus* and *T. carinatus* venom making it difficult to distinguish these two snakes by EIA at low venom concentrations (Gan et al., 2009). Here we demonstrate that binding of TSAV to *H. stephensi* venom is significantly less than for

these other two snake venoms which suggests that the herpetological inclusion of *Hoplocephalus* within the “Tiger snake group” may be of questionable clinical relevance, despite the clear similarities between the procoagulants found in *Notechis*, *Tropidechis* and *Hoplocephalus* (Joseph et al., 1999; Rao et al., 2003) and the strong phylogenetic linkage (Keogh et al., 1998). Further, the clinical features of *Hoplocephalus* envenomings are more like *Pseudonaja* envenoming cases. One reason previously supporting the inclusion of *Hoplocephalus* with *N. scutatus* and *T. carinatus* is that many cases have been reported to be positive for tiger snake venom when the sVDK is used. Our study demonstrates that at least for *H. bitorquatus* this may not be the case.

We have previously shown that all CSL antivenoms are in fact polyvalent (O’Leary and Isbister, 2009), so it might be suggested that brown snake antivenom would be similarly effective in *Hoplocephalus* envenoming. One vial of brown snake antivenom or TSAV is easily sufficient to provide concentrations greater than 50mU/mL in patients.

The *in vitro* binding studies demonstrate that TSAV concentrations of 50mU/mL are sufficient to bind the majority of free *H. stephensi* venom components at concentrations above those detected in envenomed patients (100 ng/mL). The reason this occurs is likely to be the similarity of toxin groups in Australasian elapid venoms, such as the prothrombin activators, where for example there is about 98% similarity in the prothrombin activators of *H. stephensi* and *T. carinatus*. (Rao et al., 2003) However, Fig. 5 does indicate that the binding of TSAV to *H. stephensi* venom is not as good as *N. scutatus* venom which it is raised against or to *T. carinatus* venom which we have previously shown to be highly cross-reactive with *N. scutatus* venom (Gan et al., 2009).

A limitation of the EIA used here is that rabbit anti-IgG was only raised against *H. stephensi* venom and we did not have antibodies to the other two *Hoplocephalus* venoms. Unlike previous studies using EIA to detect *Pseudonaja* venom (O’Leary et al., 2006; Isbister et al., 2007), where there appears to be significant cross-reactivity between species (*P. textilis* and *P. nuchalis*), we were unable to detect venom in 2 of 3 envenomed *H. bungaroides* cases and one envenomed *H. bitorquatus* case.

5. Conclusion

Hoplocephalus spp. envenoming causes VICC and systemic symptoms and is clinically similar to uncomplicated brown snake (*Pseudonaja* spp.) envenoming. Previous studies with EIA and *in vitro* studies here suggest there is minimal cross reactivity between *Hoplocephalus* and both *N. scutatus* and *T. carinatus*. Within the *Hoplocephalus* genus itself, the venoms appear to be antigenically distinct so that our EIA, using polyclonal antibodies raised against *H. stephensi*, did not reliably detect venoms from other snakes in the genus. *Hoplocephalus* envenoming should be treated as a unique envenoming syndrome and not grouped with *Notechis* or *T. carinatus*. Based on *in vitro* studies reported here, patients may be treated with one vial of TSAV, although one vial of brown snake antivenom may also be sufficient.

Ethical statement

Approval has been obtained from all Human Research and Ethics Committees covering institutions involved for the collection of clinical information and human serum/plasma.

Funding

The study was supported in part by NHMRC Project Grant ID490305. GKI is supported by an NHMRC Clinical Career Development Award ID605817.

Conflict of interest

None declared.

References

- Brown, S.G., 2004. Clinical features and severity grading of anaphylaxis. *J. Allergy Clin. Immunol.* 114 (2), 371–376.
- Chew, M.S., Guttormsen, A.B., et al., 2003. Exotic snake bite: a challenge for the Scandinavian anesthesiologist? *Acta. Anaesthesiol. Scand.* 47 (2), 226–229.
- Churchman, A., O’Leary, M.A., et al., 2010. Clinical effects of red-bellied black snake (*Pseudechis porphyriacus*) envenoming and correlation with venom concentrations: Australian Snakebite Project (ASP-11). *Med. J. Aust.* 193 (11–12), 696–700.
- Clancy, A.M., White, J., et al., 1997. The effect of species and geographical origin of snakes on the identification of their venom using a commercial assay. *Med. J. Aust.* 167 (1), 56.
- Comadira, G.P., Green, D., 1995. Three case of envenomation by Stephen’s banded snakes. *Emerg. Med. Australas* 7 (1), 4.
- Flecker, H., 1952. Bite from broad-headed snake: *Hoplocephalus bungaroides* (Boie). *Med. J. Aust.* 1 (11), 368–369.
- Fry, B.G., Masci, P.P., et al., 2000. Severe Defibrination Coagulopathy Resulting from Envenomation by the Australian Elapids *Hoplocephalus Bungaroides* (Broad-headed Snake) and *Hoplocephalus Stephensi*. (Stephen’s Banded Snake) XIIIth World Congress on Animal, Plant and Microbial Toxins, Paris, IST.
- Gan, M., O’Leary, M.A., et al., 2009. Envenoming by the rough-scaled snake (*Tropidechis carinatus*): a series of confirmed cases. *Med. J. Aust.* 191 (3), 183–186.
- Hession, M., 2007. Stephen’s Banded Snake envenomation treated with tiger snake antivenom. *Emerg. Med. Australas* 19 (5), 476–478.
- Ireland, G., Brown, S.G., et al., 2010. Changes in serial laboratory test results in snakebite patients: when can we safely exclude envenoming? *Med. J. Aust.* 193 (5), 285–290.
- Isbister, G.K., 2010. Snakebite doesn’t cause disseminated intravascular coagulation: coagulopathy and thrombotic microangiopathy in snake envenoming. *Semin. Thromb. Hemost.* 36 (4), 444–451.
- Isbister, G.K., O’Leary, M.A., et al., 2007. Efficacy of antivenom against the procoagulant effect of Australian brown snake (*Pseudonaja* sp.) venom: in vivo and in vitro studies. *Toxicon* 49 (1), 57–67.
- Isbister, G.K., Brown, S.G., et al., 2008. Current use of Australian snake antivenoms and frequency of immediate-type hypersensitivity reactions and anaphylaxis. *Med. J. Aust.* 188 (8), 473–476.
- Isbister, G.K., Duffull, S.B., et al., 2009. Failure of antivenom to improve recovery in Australian snakebite coagulopathy. *QJM* 102 (8), 563–568.
- Isbister, G.K., O’Leary, M.A., et al., 2010a. Cross-neutralisation of Australian brown snake, taipan and death adder venoms by monovalent antibodies. *Vaccine* 28 (3), 798–802.
- Isbister, G.K., Scorgie, F.E., et al., 2010b. Factor deficiencies in venom-induced consumption coagulopathy resulting from Australian elapid envenomation: Australian Snakebite Project (ASP-10). *J. Thromb. Haemost* 8 (11), 2504–2513.
- Joseph, J.S., Chung, M.C., et al., 1999. Amino acid sequence of trocarnin, a prothrombin activator from *Tropidechis carinatus* venom: its structural similarity to coagulation factor Xa. *Blood* 94 (2), 621–631.
- Keogh, J.S., Shine, R., et al., 1998. Phylogenetic relationships of terrestrial Australo-Papuan elapid snakes (subfamily Hydrophiinae) based on cytochrome b and 16S rRNA sequences. *Mol. Phylogenet. Evol.* 10 (1), 67–81.
- Kulawickrama, S., O’Leary, M.A., et al., 2010. Development of a sensitive enzyme immunoassay for measuring taipan venom in serum. *Toxicon* 55 (8), 1510–1518.

- O'Leary, M.A., Isbister, G.K., 2009. Commercial monovalent antivenoms in Australia are polyvalent. *Toxicon* 54 (2), 192–195.
- O'Leary, M.A., Isbister, G.K., et al., 2006. Enzyme immunoassays in brown snake (*Pseudonaja* spp.) envenoming: detecting venom, antivenom and venom-antivenom complexes. *Toxicon* 48 (1), 4–11.
- Rao, V.S., Joseph, J.S., et al., 2003. Group D prothrombin activators from snake venom are structural homologues of mammalian blood coagulation factor Xa. *Biochem. J.* 369 (Pt 3), 635–642.
- Sampson, H.A., Munoz-Furlong, A., et al., 2006. Second symposium on the definition and management of anaphylaxis: summary report—second national institute of allergy and infectious disease/food allergy and anaphylaxis network symposium. *J. Allergy Clin. Immunol.* 117 (2), 391–397.
- Sutherland, S.K., Tibballs, J., 2001. Genus *Hoplocephalus*. In: Sutherland, S. K., Tibballs, J. (Eds.), *Australian Animal Toxins*, vol. 2. Oxford University Press, Melbourne, pp. 209–219.
- White, J., 2001. *CSL Antivenom Handbook*. CSL Ltd, Melbourne.